ISSN 1220-8841 (Print)
ISSN 2344-4959 (Online)

ROMANIAN
NEUROSURGERY

Vol. XXXX | No. 3 September 2026

Median nerve giant schwannoma: a case report and literature review

K. Shah,
R. Padshala,
V. Shah,
K. Soladhra,
D. Velani,
M. N. Imam,
K. Shah,
K. Vala,
V. Sutariya

DOI: 10.33962/roneuro-2026-057

Romanian Neurosurgery (2026) XXXX (3): pp. 247-250
DOI: 10.33962/roneuro-2026-057
www.journals.lapub.co.uk/index.php/roneurosurgery

Median nerve giant schwannoma: a case report and literature review

K. Shah[1], R. Padshala[1], V. Shah[1], K. Soladhra[1], D. Velani[1], M. N. Imam[1], K. Shah[2], K. Vala[1], V. Sutariya[1]

[1] Department of Neurosurgery, Smt. NHL Municipal Medical College, Ahmedabad, Gujarat, INDIA
[2] Department of Neurosurgery, Zydus Hospital, Ahmedabad, Gujarat, INDIA

ABSTRACT

Background: Schwannomas are benign peripheral nerve sheath tumors arising from Schwann cells, most commonly affecting the median nerve in the upper extremity. Although typically slow-growing and asymptomatic, they can present with pain, swelling, or neurologic symptoms due to nerve compression. Accurate diagnosis and appropriate management are crucial to ensure complete resection and preservation of nerve function.

Case presentation: We report a case of a 30-year-old male presenting with a 3-year history of a painless, gradually enlarging swelling on the medial aspect of the distal left arm. On examination, a 6×6 cm, well-circumscribed, soft, and tender mass was noted, with mild motor weakness in thumb opposition and finger flexion. Magnetic resonance imaging (MRI) revealed a well-defined lesion within the muscular plane, arising from the median nerve, consistent with a benign peripheral nerve sheath tumor. The patient underwent complete surgical excision with preservation of the nerve fascicles, without the need for nerve grafting. Histopathological examination confirmed the diagnosis of schwannoma. Postoperatively, the patient experienced no new neurological deficits and showed clinical improvement.

Conclusion: This case highlights the importance of considering schwannomas in the differential diagnosis of soft tissue masses in the upper limb, particularly when associated with subtle neurological findings. Imaging modalities such as MRI and ultrasonography play a key role in preoperative assessment. Surgical enucleation remains the treatment of choice, offering excellent outcomes with low recurrence rates and preservation of nerve function. This report reinforces current literature on the clinical presentation, diagnostic approach, and successful management of median nerve schwannomas.

Keywords
median nerve, schwannomas, benign peripheral nerve sheath tumors, surgical excision

Corresponding author:
Renish Padshala

Smt. NHL Municipal Medical College, Ahmedabad, India

renex.patel@gmail.com

Copyright and usage. This is an Open Access article, distributed under the terms of the Creative Commons Attribution Non-Commercial No Derivatives License (https://creativecommons.org/licenses/by-nc-nd/4.0/) which permits non-commercial re-use, distribution, and reproduction in any medium, provided the original work is unaltered and is properly cited.

The written permission of the Romanian Society of Neurosurgery must be obtained for commercial re-use or in order to create a derivative work.

ISSN 2344-4959 (online)
ISSN 1220-8841 (print)

© Romanian Society of Neurosurgery

First published
September 2026 by
London Academic Publishing
www.london-ap.uk

INTRODUCTION

Peripheral nerve sheath tumors are a group of neoplasms originating from the cells surrounding peripheral nerves. Among these, schwannomas, also known as neurilemomas, are the most common benign variant (1,2). These tumors typically exhibit slow growth and are generally benign. While they can occur sporadically or be associated with genetic disorders, schwannomas commonly affect individuals between the third and sixth decades of life (3).

This report aims to present a case of median nerve sheath tumor schwannoma and review the relevant literature concerning its presentation, diagnosis, and management.

Literature review

Pathophysiology and characteristics

Schwannomas originate from Schwann cells and are typically encapsulated, solitary tumors (3,4). Histologically, they are characterized by Antoni A areas (dense cellularity with Verocay bodies) and Antoni B areas (myxoid, hypocellular regions). The presence of S100 protein on histochemical analysis further confirms their diagnosis and helps differentiate them from other soft tissue tumors like lipomas, neurofibromas, and gangliomas (2,3). Their encapsulated nature often facilitates complete surgical enucleation with preservation of nerve fascicles (5,6).

Clinical presentation

Median nerve sheath tumors can initially be asymptomatic or present as a local bulging or discomfort. As the tumor grows, it may compress adjacent tissues, leading to symptoms such as paresthesia, a positive Tinel's sign, pain, and dysesthesia (3). Pain is a frequent complaint, and a palpable mass on the flexor aspect of the forearm is common (7). In some instances, multiple schwannomas on the median nerve can lead to symptoms that might be misdiagnosed as carpal tunnel syndrome (8). Motor deficits are rare in benign cases and may suggest malignancy (3). The asymptomatic nature and slow evolution can lead to delayed diagnosis (9).

Diagnosis

Diagnosis of median nerve sheath tumors can be challenging due to non-specific symptoms and potential confusion with other soft tissue tumors (3). A combination of clinical assessment and imaging is crucial. Magnetic Resonance Imaging is the preferred imaging modality as it provides detailed information on tumor extent and its relationship with surrounding structures, aiding in surgical planning (3,8). Ultrasonography is a valuable preliminary tool, revealing avascular, well-limited masses and assisting in the characterization of tumors and peripheral neuropathies (3,10,11). Computed Tomography can also be used in conjunction with other imaging for assessment (7). Histopathology: The definitive diagnosis is typically made through histopathological examination of the excised tumor (2,3). Biopsies are generally not recommended due to risks of neurological injury or tumor cell translocation (3).

Treatment

Surgical resection is the most common and curative treatment for benign median nerve sheath tumors (1,3,12). The primary goal is complete tumor removal while preserving nerve function (5). Due to their eccentric growth, schwannomas can often be enucleated without damaging nerve fascicles (3,5,6). Surgical loupes or microscopic magnification are commonly used to ensure precise dissection and nerve preservation (5,6). Intraoperative ultrasound can also assist in visualizing the lesion and ensuring complete removal (3).

Prognosis and recurrence

The prognosis for schwannomas after surgical removal is generally excellent, with a low recurrence rate and minimal potential for malignant transformation (2,9,13). Complete resection is associated with favorable outcomes (12,14). While patients may experience temporary neurological symptoms post-surgery, these typically resolve within a few months (3).

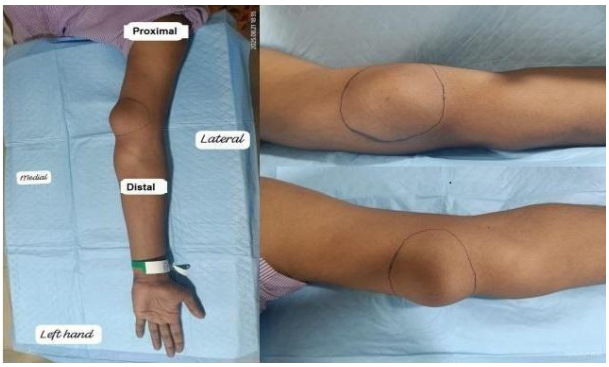

Figure 1. Clinical images of the left arm swelling.

Case report

A 30 year old man presented with swelling at left upper limb- lower 1/3 of arm on medial side since 3 years. He referred only to the local pain of touching it. In a neurologic exam, he had a strength grade 4 for thumb opposition and finger flexion. Clinically he had 6x6 cm globular swelling on the medial aspect of

the lower 1/3 of left arm, soft with well defined margin fixed to underlying structures, moving along length of arm, tenderness present, overlying skin appears normal (Figure 1). He underwent an MRI that showed a lesion suggestive of a large benign peripheral nerve sheath tumor in the intramuscular plane at the medial aspect of the distal left arm arising from the median nerve (Figure 2). He was subjected to a tumoral resection (Figure 3). The nerve graft was not necessary. The patient did not report new neurological impairment. The histopathology was compatible with Schwannoma (Figure 4).



Figure 2. MRI of the left arm: (a) axial, (b) sagittal and (c) coronal sections.

Discussion

The present case of schwannoma of left median nerve aligns with several findings in the literature regarding median nerve sheath tumors. For instance, the patient's age, gender and symptom are consistent with Chaves *et al.* (3). The diagnostic pathway, relying on MRI and ultrasound, are in line with recommended practices for characterizing these tumors and differentiating them from other soft tissue masses (3).



Figure 3. Pathological specimen of the swelling (A, B).

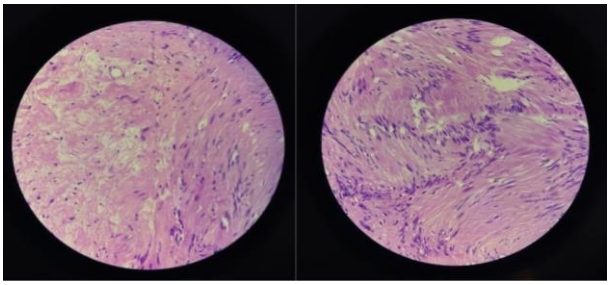

Figure 4. Histopathologic examination shows (A) hypocellular Antoni A and hypercellular Antoni B areas and (B) Verocay bodies, confirming the diagnosis of benign schwannoma.

The successful surgical excision with preservation of nerve function and positive neurological recovery further supports the literature's emphasis on complete surgical removal as the gold standard for benign schwannomas, often achievable without significant neurological sequelae (5,6). This case also underscores the importance of considering these tumors in the differential diagnosis of swelling at left upper limb- lower especially given their non-specific presentation (3,8).

Conclusion

This case reports the case of a schwannoma arising from the left median nerve, presenting as a slow-growing, painless swelling in the distal arm. The tumor was successfully excised without postoperative neurological complications contributing to the understanding of median nerve sheath tumors. It highlights the importance of thorough clinical and radiological evaluation for accurate diagnosis and demonstrates the effectiveness of surgical management in achieving favorable outcomes with nerve preservation. Further research, including larger case series, would continue to refine our understanding of rare presentations and long-term prognoses of these tumors.

References

1. Chang, CH., Wang, JP., Huang, YC. *et al.* Excision of large median and ulnar nerve schwannomas: a case series. BMC Surg 24, 284 (2024).
2. Ansilata Marlyn Anesly, Faisal Ameer, Hillol Kanti Pal EMJ Neurol. 2020;8[1]:103-107. Case Report of Schwannomas: Benign Tumour of the Peripheral Nerve Sheath. DOI/10.33590/emjneurol/19-00203.
3. Jennyfer Paulla Galdino Chaves, Emanuella Roberta Iná Cirino Luis Henrique Albuquerque Sousa, Robinson Antonio Menegotto Marques. Giant Schwannoma of the Median Nerve: A Case Report and Literature Review, Asian J Oncol 2019;5:36–38, DOI https://doi.org/10.1055/s-0039-1696591 ISSN 2454-6798.
4. Salar M, Kaye MB. Multiple Schwannomas of the Median Nerve: A Case Report and Review of Literature. J Orthop Case Rep. 2020 Sep;10(6):60-63. doi: 10.13107/jocr.2020.v10.i06.1876. PMID: 33489971; PMCID: PMC7815672.
5. Kapoor, R. and Saxena, B.R. (2018) Case Series of Peripheral Nerve Sheath Tumours: Schwanoma. Journal of Clinical and Diagnostic Research,12,PR01-PR03.
6. Konstantinos C Xarchas, Georgia's Kyriakopoulos, Maria Vlachou and Spyros Manthas. Median Nerve Schwannoma of the Hand and Wrist: 3 Cases. DOI: 10.2174/1874325001913010290, 2019, 13, 290-294
7. Padasali PS, Shankaregowda VS, Kshirsagar SD. Median nerve schwannoma: A case and review of literature. Asian J Neurosurg. 2015 Jul-Sep;10(3):212-5. doi: 10.4103/1793-5482.161178. PMID: 26396609; PMCID: PMC4553734.
8. Aslam N, Kerr G. Multiple schwannomas of the median nerve: a case report and literature review. Hand Surg. 2003 Dec;8(2):249-52. doi: 10.1142/s0218810403001741. PMID: 15002106.
9. Boufettal M, Azouz M, Rhanim A, Abouzahir M, Mahfoud M, Bardouni AE, Berrada MS, Yaacoubi ME. Schwannoma of the median nerve: diagnosis sometimes delayed. Clin Med Insights Case Rep. 2014 Jul 29;7:71-3. doi: 10.4137/CCRep.S16686. PMID: 25125990; PMCID: PMC4125423.
10. Slimane K, Sbai MA, Elfeki F, Maalla R (2016) The Motor Branch of the Median Nerve, a Rare Localization of Schwannoma. J Clin Exp Orthop 2:18. doi: 10.4172/2471-8416.100018
11. Upadhyaya V, Choudur HN. Imaging in peripheral neuropathy: Ultrasound and MRI. Indian J Musculoskelet Radiol 2021;3(1):14-23.
12. Zipfel J, Al-Hariri M, Gugel I, Grimm A, Steger V, Ladurner R, Krimmel M, Tatagiba M, Schuhmann MU. Surgical Management of Sporadic Peripheral Nerve Schwannomas in Adults: Indications and Outcome in a Single Center Cohort. Cancers (Basel). 2021 Mar 1;13(5):1017. doi: 10.3390/cancers13051017. PMID: 33804463; PMCID: PMC7957633.
13. Galaz Hernández R, Granados Flores AA, Garcia Palazuelos Ramirez JM, Rodriguez Madrid TC, Gonzalez Soto JR, Arriola Rios DI, Sierra Reyes MC, Rubio Vega PG. Cervical Schwannoma: Diagnosis and Treatment in a Second-Level Hospital in Mexico. Cureus. 2025 Jul 7;17(7):e87481. doi: 10.7759/cureus.87481. PMID: 40777668; PMCID: PMC12328070.
14. A.R. Prabhuraj, Sarthak Mehta, Nishanth Sadashiva, Nupur Pruthi, Arivazhagan Arima, Kannepalli Narasingha Rao, Vikas Vazhayil, Manish Beniwal, Abhinith Shashidhar, Gyani Jail Singh Birua, Sampath Somanna, Factors predicting recurrence in benign spinal nerve sheath tumors: A retrospective study of 457 patients from a single institution, Journal of Clinical Neuroscience, Volume 114, 2023, Pages 158-165,ISSN 0967-5868, https://doi.org/10.1016/j.jocn.2023.06.019.