ISSN 1220-8841 (Print)
ISSN 2344-4959 (Online)

ROMANIAN
NEUROSURGERY

Vol. XXXX | No. 3 September 2026

Giant cranial metastasis of hepatocellular carcinoma: a rare case report

Vuk Aleksić,
Nenad Lalović,
Radmila Aleksić,
Emir Bilalović,
Nikolina Dukić,
Milorad Bjelović

DOI: 10.33962/roneuro-2026-053

Romanian Neurosurgery (2026) XXXX (3): pp. 231-235
DOI: 10.33962/roneuro-2026-053
www.journals.lapub.co.uk/index.php/roneurosurgery

Giant cranial metastasis of hepatocellular carcinoma: a rare case report

Vuk Aleksić[1,2], Nenad Lalović[2,3], Radmila Aleksić[4], Emir Bilalović[5], Nikolina Dukić[2,3], Milorad Bjelović[2,6]

[1] Department of Neurosurgery, Clinical Hospital Center Zemun, Belgrade, SERBIA
[2] Faculty of Medicine Foča, University of East Sarajevo, Foča, BOSNIA AND HERZEGOVINA
[3] University Hospital Foča, Foča, BOSNIA AND HERZEGOVINA
[4] Department of Head and Neck Surgery, Clinical Hospital Center Zemun, Belgrade, SERBIA
[5] General Hospital Novi Pazar, Novi Pazar, SERBIA
[6] Clinic for Thoracic Surgery, Institute for Pulmonary Diseases of Vojvodina, Sremska Kamenica, SERBIA

Keywords
hepatocellular carcinoma, cranial metastasis, brain metastasis

ABSTRACT

Brain metastases from hepatocellular carcinoma (HCC) are rare and usually occur in patients with advanced systemic disease. Cranial metastasis as the first manifestation of previously undiagnosed HCC is particularly uncommon.

We report a 70-year-old HCV-positive man with a rapidly growing cranial mass initially considered to be a lipoma. Within two months, the lesion reached an enormous size, with extensive cranial destruction and significant intracranial extension. Further diagnostic work-up revealed a previously unknown HCC without other detectable distant metastases. Complete surgical resection and cranioplasty were performed, and histopathology confirmed metastatic HCC. Five months after surgery, there was no evidence of local recurrence, although a new scapular lesion suspicious for metastatic disease subsequently developed and the patient declined further treatment.

Giant cranial metastasis may rarely represent the first manifestation of HCC. Surgical resection can provide effective local control, particularly in large symptomatic lesions with significant mass effect. Given the rarity of this condition and the absence of standardized treatment guidelines, an individualized multidisciplinary approach remains essential.

Corresponding author:
Vuk Aleksić

Clinical Hospital Center Zemun, Belgrade, Serbia

aleksicvuk@hotmail.com

Copyright and usage. This is an Open Access article, distributed under the terms of the Creative Commons Attribution Non-Commercial No Derivatives License (https://creativecommons.org/licenses/by-nc-nd/4.0/) which permits non-commercial re-use, distribution, and reproduction in any medium, provided the original work is unaltered and is properly cited.

The written permission of the Romanian Society of Neurosurgery must be obtained for commercial re-use or in order to create a derivative work.

ISSN 2344-4959 (online)
ISSN 1220-8841 (print)

© Romanian Society of Neurosurgery

First published
September 2026 by
London Academic Publishing
www.london-ap.uk

INTRODUCTION

Brain metastases secondary to hepatocellular carcinoma (HCC) are a rare complication of advanced disease, occurring in approximately 1% of patients [1, 2]. Until recently, this complication received relatively limited clinical attention, largely because the unfavorable prognosis of HCC often resulted in patients succumbing to their primary disease before neurological manifestations became clinically apparent [1].

In recent years, however, improvements in diagnostic techniques and therapeutic strategies for HCC have prolonged patient survival and contributed to an increasing recognition of brain metastases during the course of the disease [1, 3].

Despite considerable progress in the treatment of both primary HCC and intracranial metastatic disease, the prognosis of patients who develop secondary deposits in the brain remains poor, with only limited improvement in clinical outcomes [4]. Also, patients with brain metastases from HCC commonly present with advanced-stage disease and a substantial systemic tumor burden. Concurrent extracranial metastases have been reported in more than 90% of cases, with the lungs representing the most frequent metastatic site (69.4–75.6%), followed by bone (18–25.8%), lymph nodes, and adrenal glands [1, 5]. Rarely, cerebral involvement may occasionally occur in patients with early-stage HCC or even in the absence of other documented extrahepatic metastases [1, 6].

We present the case of a 70-year-old patient with hepatocellular carcinoma (HCC) and chronic hepatitis C virus (HCV) infection. The epicranial lesion, initially considered to be a lipoma, exhibited remarkably rapid growth, developing into an enormous mass within only two months. Further diagnostic evaluation revealed an epicranial HCC metastasis with a significant intracranial component. Notably, no other metastatic sites were identified, making this presentation particularly unusual.

Case report

A 70-year-old male initially presented to a plastic surgeon because of an epicranial mass. Based on its clinical appearance, the lesion was initially considered to be a lipoma, and surgical excision or clinical observation was advised. However, over a period of only two months, the lesion demonstrated remarkably rapid growth, progressing to an enormous mass (Figure 1).



Figure 1. Clinical appearance of the patient upon admission to our institution, showing a large, firm, immobile tumor mass involving the left side of the scalp.

Upon reassessment by the plastic surgeon, the unusual growth pattern raised concern for a more aggressive underlying pathology, and the patient was urgently referred for computed tomography of the head, which showed a large destructive lesion with both intracranial and extracranial extension, causing significant mass effect on the underlying brain parenchyma (Figure 2). The patient was immediately referred to our institution for neurosurgical evaluation.

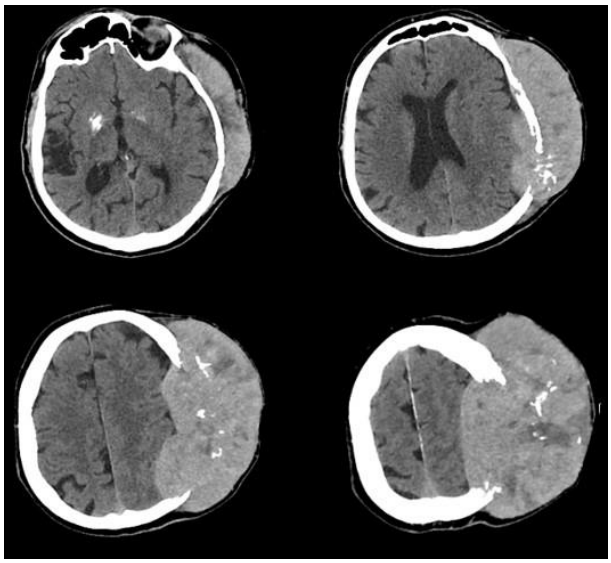

Figure 2. Preoperative head CT scan demonstrating a large destructive cranial lesion with both intracranial and extracranial extension, causing significant mass effect on the underlying brain parenchyma.

As part of the staging work-up, CT examinations of the chest, abdomen, and pelvis were performed. Abdominal CT revealed an irregular hypodense lesion in segment VII of the liver, measuring approximately 53 × 35 mm in axial dimensions, accompanied by thrombosis of the right branch of the portal vein. Segment VI demonstrated a diffusely heterogeneous appearance, reduced volume, and capsular retraction. The radiological findings were considered highly suspicious for a primary hepatic malignancy, most likely hepatocellular carcinoma (HCC). No other distant metastatic lesions were identified on the initial staging examinations. Routine laboratory and serological investigations additionally revealed that the patient was positive for hepatitis C virus (HCV) infection.

Given the extensive cranial lesion, its rapid progression, and the development of clinical symptoms, surgical treatment was undertaken

without delay. The epicranial metastatic mass, which also had a significant intracranial component, was completely resected (Figure 3A–C). Due to the extensive cranial defect following tumor removal, cranioplasty with an artificial bone substitute was performed during the same procedure. The patient was satisfied with the postoperative cosmetic outcome (Figure 3D). Histopathological examination of the resected lesion confirmed its metastatic origin from HCC. Follow-up brain CT demonstrated satisfactory postoperative findings, with no evidence of residual tumor and satisfactory cranioplasty reconstruction (Figure 4).

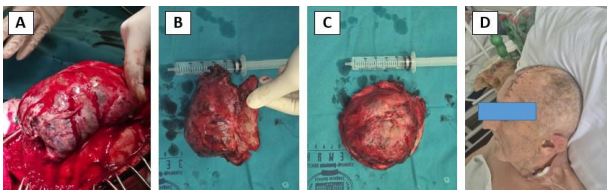

Figure 3. (A–C) the intraoperative findings, including en bloc resection of the tumor. (D) a satisfactory cosmetic outcome following surgery.

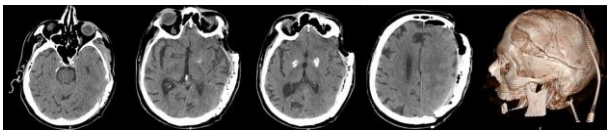

Figure 4. Postoperative CT demonstrating complete tumor resection with no evidence of residual disease and successful reconstruction of the cranial defect with cranioplasty.

Following surgery, the patient was evaluated by a multidisciplinary oncology team. At that time, no definitive decision regarding surgical or other oncological treatment of the primary hepatic lesion was made, and the patient was subsequently discharged home. At the five-month follow-up, the patient reported being in good general condition but declined further imaging examinations and additional oncological treatment. According to information subsequently obtained from his son, his general condition remained satisfactory. However, he developed pain in the left upper extremity associated with the appearance of a new mass in the left scapular region. The patient agreed to undergo CT examination, which demonstrated a lesion highly suspicious for a secondary metastatic deposit. Despite this finding, he declined further diagnostic evaluation and treatment.

Discussion

Brain metastases from HCC remain considerably less frequent than metastatic involvement of other organs. This low incidence has been attributed to the relatively limited propensity of HCC to spread to the central nervous system, as well as to the historically aggressive clinical course and short survival of affected patients, which may limit the time available for brain metastases to become clinically apparent [1, 7]. Nevertheless, the reported incidence of brain metastases from HCC has gradually increased over recent decades, likely reflecting improvements in diagnostic methods and prolonged survival resulting from advances in the treatment of primary HCC [1]. Our case represents an unusual clinical presentation, as the cranial metastasis was the first manifestation of an otherwise previously unrecognized HCC. The patient had no prior symptoms or clinical findings suggestive of primary liver malignancy, and no other metastatic lesions were detected during the initial staging. Moreover, the prominent extracranial component of the cranial lesion was initially mistaken for a benign fatty mass, presumed to be a lipoma. Only after its strikingly rapid growth over a two-month period and the onset of headache was further diagnostic evaluation performed, revealing an extensive destructive cranial lesion with both extracranial and significant intracranial components. Subsequent systemic imaging identified the previously undiagnosed hepatic tumor, while histopathological examination of the resected cranial mass confirmed metastatic HCC. Thus, in our patient, the cranial metastasis not only preceded the diagnosis of the primary malignancy but was also the clinical finding that ultimately led to the recognition of HCC.

Due to the rarity of brain metastases from HCC and their generally unfavorable prognosis, a standardized therapeutic strategy has not yet been clearly established [8]. Treatment should therefore be individualized according to the patient's neurological and general condition, liver function, expected survival, extent of systemic disease, number and characteristics of intracranial lesions, and status of the primary HCC. A multidisciplinary approach is essential, with available therapeutic options including surgical resection, stereotactic radiosurgery (SRS), whole-brain radiotherapy (WBRT), systemic therapy, and supportive treatment [1, 9, 10]. Surgical resection remains an important

treatment option, particularly in patients with a solitary or limited number of brain metastases, good performance status, and controlled or limited systemic disease. Surgery is especially valuable for large symptomatic lesions associated with significant mass effect, as it provides immediate decompression, may improve neurological symptoms, and allows histopathological confirmation of the diagnosis [1, 11]. Although only a relatively small proportion of patients with brain metastases of HCC undergo surgery, mainly because of advanced liver disease and poor general condition, retrospective studies suggest that appropriately selected patients may benefit from an aggressive surgical approach [12]. In our patient, the exceptionally large size of the cranial metastasis, its extensive destruction of the cranial bone, significant intracranial component, and pronounced mass effect made surgical resection the most appropriate initial therapeutic approach. Complete tumor removal provided immediate local control and enabled simultaneous reconstruction of the extensive cranial defect by cranioplasty. Furthermore, histopathological examination of the resected lesion established the metastatic nature of the tumor and ultimately led to the diagnosis of the previously unrecognized primary HCC.

This case illustrates an unusual presentation of hepatocellular carcinoma, in which a giant cranial metastasis with a significant intracranial component represented the first clinical manifestation of an otherwise previously unrecognized primary malignancy. Due to the exceptional size of the lesion, extensive cranial involvement, and significant mass effect, surgical resection represented the most appropriate therapeutic option and resulted in complete local tumor removal and successful cranial reconstruction. Despite the patient's subsequent decision to decline further oncological treatment, no local recurrence was observed five months after surgery. A new lesion subsequently developed in the scapular region, highly suggestive of further metastatic dissemination; however, the patient again declined additional treatment.

Given the rarity of brain metastases from HCC and the lack of standardized treatment guidelines, management should be tailored to each patient. General principles for the treatment of brain metastases should be integrated with the patient's neurological status, systemic disease burden, liver function, characteristics of the intracranial lesion, and individual treatment preferences. Our case emphasizes that, even in advanced HCC, aggressive surgical treatment may provide effective local disease control in carefully selected patients, particularly when a large symptomatic metastasis produces substantial mass effect. An individualized, multidisciplinary approach therefore remains essential in the management of these rare and challenging cases.

References

1. Wang S, Wang A, Lin J, Xie Y, Wu L, Huang H, Bian J, Yang X, Wan X, Zhao H, Huang J. Brain metastases from hepatocellular carcinoma: recent advances and future avenues. Oncotarget. 2017;8(15):25814-25829.
2. Menis J, Fontanella C, Follador A, Fasola G, Aprile G. Brain metastases from gastrointestinal tumours: tailoring the approach to maximize the outcome. Crit Rev Oncol Hematol. 2013;85:32–44.
3. Jiang XB, Ke C, Zhang GH, Zhang XH, Ke S, Chen ZP, Mou YG. Brain metastases from hepatocellular carcinoma: clinical features and prognostic factors. BMC Cancer. 2012;12:1–9.
4. Xu Q, Pan W, Feng Y, Ke Y, Ying T, Zhou Y. Gamma Knife Surgery for Brain Metastasis from Hepatocellular Carcinoma. PLoS One. 2014;9:e88317.
5. Lim S, Lee S, Lim JY, Park JS, Seong JS, Chang WS, Han KH, Choi HJ. Hepatocellular carcinoma specific graded prognostic assessment can predict outcomes for patients with brain metastases from hepatocellular carcinoma. J Neurooncol. 2014;120:199–207
6. Toshikuni N, Morii K, Yamamoto M. Radiotherapy for multiple brain metastases from hepatocellular carcinomas. World Journal of Gastroenterology. 2007;13:4520–2.
7. Chen SF, Tsai NW, Lui CC, Lu CH, Huang CR, Chuang YC, Cheng YF, Kuo CH, Chang WN. Hepatocellular carcinoma presenting as nervous system involvement. European Journal of Neurology. 2007;14:408–12.
8. Han MS, Moon KS, Lee KH, Cho SB, Lim SH, Jang WY, Jung TY, Kim IY, Jung S. Brain metastasis from hepatocellular carcinoma: the role of surgery as a prognostic factor. BMC Cancer. 2013;13:349–54.
9. Bertolini F, Spallanzani A, Fontana A, Depenni R, Luppi G. Brain metastases: an overview. CNS Oncology. 2015;4:37–46.
10. Dawe DE, Greenspoon JN, Ellis PM. Brain metastases in non-small-cell lung cancer. Clin Lung Cancer. 2014;15:249–57.
11. Soffietti R, Cornu P, Delattre JY, Grant R, Graus F, Grisold W, Heimans J, Hildebrand J, Hoskin P, Kalljo M, Krauseneck P, Marosi C, Siegal T, *et al.* EFNS Guidelines

on diagnosis and treatment of brain metastases: report of an EFNS Task Force. Eur J Neurol;13:674–81.

12. Choi HJ, Cho BC, Sohn JH, Shin SJ, Kim SH, Kim JH, Yoo NC. Brain metastases from hepatocellular carcinoma: prognostic factors and outcome: brain metastasis from HCC. J Neurooncol. 2009;91:307–13.