ISSN 1220-8841 (Print)
ISSN 2344-4959 (Online)

ROMANIAN
NEUROSURGERY

Vol. XXXX | No. 3 September 2026

Large falcotentorial meningioma mimicking a pineal region tumor: diagnostic and surgical challenges

Shikhar Chohan,
Sana Ahuja,
Sufian Zaheer,
Vishesh Guglani,
Anant Sharma

DOI: 10.33962/roneuro-2026-066

Romanian Neurosurgery (2026) XXXX (3): pp. 294-298
DOI: 10.33962/roneuro-2026-066
www.journals.lapub.co.uk/index.php/roneurosurgery

Large falcotentorial meningioma mimicking a pineal region tumor: diagnostic and surgical challenges

Shikhar Chohan[1], Sana Ahuja[1], Sufian Zaheer[1], Vishesh Guglani[2], Anant Sharma[3]

[1] Department of Pathology, Vardhman Mahavir Medical College and Safdarjung Hospital, New Delhi, INDIA
[2] Department of Neurosurgery, Vardhman Mahavir Medical College and Safdarjung Hospital, New Delhi, INDIA
[3] Department of Radiology, Vardhman Mahavir Medical College and Safdarjung Hospital, New Delhi, INDIA

Keywords
meningioma, Parinaud syndrome, hydrocephalus, pineal region tumor, falcotentorial meningioma, microsurgery, interhemispheric approach

ABSTRACT

Background: Pineal region tumors are uncommon and encompass a heterogeneous group of lesions. Falcotentorial meningiomas presenting as pineal region masses are rare and can closely mimic primary pineal tumors on imaging, posing a diagnostic challenge due to their deep location and proximity to critical venous structures.

Case presentation: A 50-year-old female presented with headache, vomiting, visual disturbances, and features of Parinaud's syndrome. Magnetic resonance imaging revealed a large, well-defined, homogeneously enhancing pineal region mass measuring 5.3 × 4.5 × 4.2 cm with obstructive hydrocephalus and displacement of deep venous structures. Serum and cerebrospinal fluid tumor markers were negative. Following ventriculoperitoneal shunting, gross total excision was performed via an interhemispheric approach. Histopathological examination confirmed a World Health Organization Grade I transitional meningioma. The postoperative course was uneventful, and the patient remained clinically stable at follow-up.

Conclusion: Falcotentorial meningiomas may mimic primary pineal region tumors, leading to diagnostic uncertainty. Recognition of this entity and careful evaluation of imaging features are essential for accurate preoperative diagnosis and appropriate surgical planning.

Corresponding author:
Sufian Zaheer

Vardhman Mahavir Medical College and Safdarjung Hospital, New Delhi, India

sufianzaheer@gmail.com

Copyright and usage. This is an Open Access article, distributed under the terms of the Creative Commons Attribution Non-Commercial No Derivatives License (https://creativecommons.org/licenses/by-nc-nd/4.0/) which permits non-commercial re-use, distribution, and reproduction in any medium, provided the original work is unaltered and is properly cited.

The written permission of the Romanian Society of Neurosurgery must be obtained for commercial re-use or in order to create a derivative work.

ISSN 2344-4959 (online)
ISSN 1220-8841 (print)

© Romanian Society of Neurosurgery

First published
September 2026 by
London Academic Publishing
www.london-ap.uk

INTRODUCTION

Pineal region tumors (PTs) are highly uncommon diseases with drastically varied histological features[1]. Pinealocytes (pineal parenchymal cells) are the most important cells in the pineal gland. Because the cells and structures next to the pineal gland are diverse, this area is linked to a number of diseases. There are three types of pineal gland cancers: lesions originating from nearby tissues, germ cell tumors, and tumors originating from the pineal parenchyma.

Astrocytoma, oligodendroglioma, glial cyst (pineal cyst), meningioma, arachnoid cyst, ependymoma, chemodectoma, epidermoid, dermoid, metastasis, aneurysm of the vein of Galen, arteriovenous malformation, and cysticercosis are further abnormalities that are located next to the gland[2].

Pineal meningiomas are rare, accounting for 8% of pineal tumours. Meningiomas exceeding 5 cm in maximum diameter in the pineal region are considered giant in prior [3]. Most of these tumours originate from the free border of the tentorium or from the junction of the falx and tentorium[4]. The pineal region's anatomy is complicated, and gaining surgical access to it is challenging. The geographical density of important neurovascular systems has traditionally made surgery a difficult technical challenge. The extraordinarily high rate of neurological impairments and mortality associated with surgical treatment has been the subject of much research in the past. The choice of surgical approach is determined by the direction of growth of the tumor and the location of the venous system, in addition to the surgeon's preference[1 4].

Headache, blurred vision, nausea, difficulty walking, and memory loss are all usual symptoms that pineal tumors can present with. Papilledema, ataxia, and aberrant eye movements, such as Parinaud syndrome (dorsal midbrain syndrome), loss of vertical gaze, nystagmus upon attempted convergence, and pseudo-Argyll Robertson pupil are common associated clinical signs[5]. Here we present a case of a 50-year-old female with an unusually massive transitional meningioma in the pineal region presenting with headache, vomiting, and blurring of vision.

Case presentation

A 50-year-old female presented to the neurology emergency with complaints of headache, vomiting and blurring of vision along with aberrant eye movements, which had been occurring for the last 7 months with progressive deterioration. A neurological assessment upon admission revealed papilledema and positive Parinaud's sign.

A contrast-enhanced magnetic resonance imaging (MRI) study was planned, which showed a homogeneously enhancing, well-defined solid lesion measuring 5.3 × 4.5 × 4.2 cm in the pineal region. The lesion was hypointense on T1-weighted and hyperintense on T2/FLAIR [Figure 1, 2]. Diffusion-Weighted Imaging (DWI) images showed no diffusion restriction within the pineal region mass. The lesion showed peripheral calcification and was seen abutting the tectal plate. Given its proximity to the midbrain and resultant tectal compression, the lesion radiologically simulated a midbrain mass. The mass compressed the quadrigeminal plate and displaced the vein of Galen inferiorly, accounting for the patient's symptoms. Extrinsic compression over the aqueduct of Sylvius with resultant acute moderate proximal hydrocephalus and transependymal periventricular ooze was noted. Consequently, a ventriculoperitoneal shunt was placed. Pre-operative MR venography showed the tumor displacing the internal cerebral veins inferiorly but preserving flow.

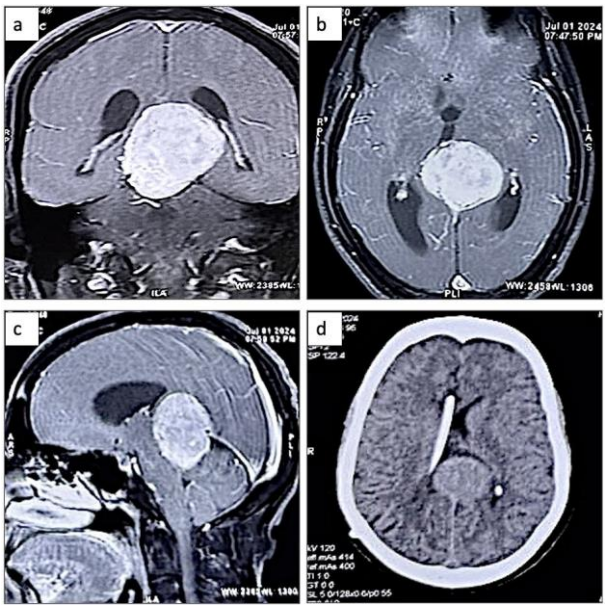

Figure 1. Radiological images: Coronal T1 contrast images showing a homogenously enhancing well-defined solid lesion; Axial T1 contrast images showing a homogeneously enhancing, well-defined solid lesion; Sagittal T1 contrast images showing a homogeneously enhancing, well-defined solid lesion; Non-contrast CT shows a slightly hyperdense extra-axial mass with peripheral calcification.

Serum and CSF tumor markers did not provide any noteworthy results. A provisional diagnosis of bilateral falcotentorial meningioma was made, and a left parieto-occipital horseshoe craniotomy with gross total excision of the tumor via the interhemispheric approach was planned under general anaesthesia.

The patient was positioned prone with the head fixed in a Mayfield clamp and slightly tilted to the left. A U-shaped incision was made in the left parieto-occipital region, followed by a parieto-occipital craniotomy and durotomy. A greyish-white, highly vascular, suckable tumor attached to the falx cerebri and tentorium cerebelli was identified and excised completely via the interhemispheric approach. The wound was closed in layers. Postoperative recovery was uneventful, and the patient was discharged on day 5.

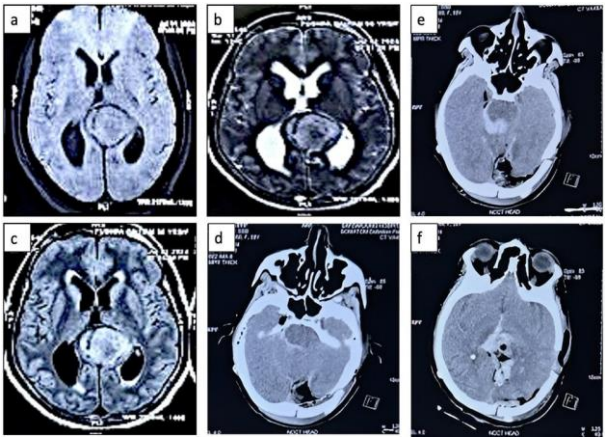

Figure 2. Radiological images: Axial T1 precontrast images showing hypointense well defined solid lesion; Axial T2-weighted MR images showing a hyperintense pineal region mass compressing the quadrigeminal plate with resultant obstructive hydrocephalus; Axial FLAIR MRI images showing a hyperintense pineal region mass compressing the quadrigeminal plate with resultant obstructive hydrocephalus and periventricular hyperintensity suggestive of transependymal CSF seepage; (d-f) Postoperative CT showing gross total excision of the lesion with haemorrhagic changes within the surgical cavity and preserved surrounding parenchyma.

At 12-month follow-up, the patient remained neurologically intact with no radiological recurrence. Postoperative MRI could not be obtained as the patient returned to a remote village and was unable to report for imaging follow-up. However, a postoperative CT scan demonstrated gross total excision of the lesion with minimal postoperative hemorrhagic changes within the surgical cavity. The minor hyperdense area noted adjacent to the operative bed represented expected postoperative changes. The patient remained asymptomatic on clinical follow-up.

Pathological findings

The tumor tissue was sent for histopathological examination to the Department of Pathology in 10% formaldehyde. Multiple grey-brown to grey-white small tissue bits altogether measuring 6 × 5 × 2 cm were received for histopathological analysis. The entire tissue bit was processed.

Microscopy showed lobules, cohesive nests and whorls of plump polygonal meningothelial cells with oval nuclei, finely dispersed chromatin, indistinct cell borders, interspersed with fascicles of spindle cells exhibiting elongated nuclei and eosinophilic cytoplasm. [Figure 3] Mitotic activity was low, with no evidence of necrosis, brain invasion, or anaplasia. A final diagnosis of transitional meningioma, WHO Grade I was made.

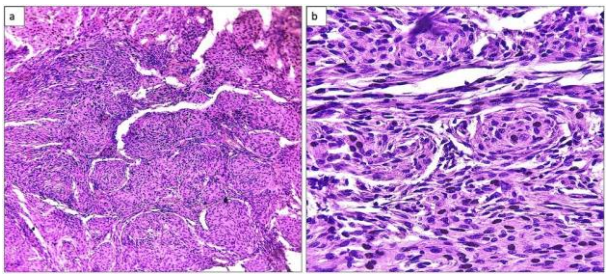

Figure 3. Histopathological photomicrographs: Low power view showing lobulated and whorled architecture, with syncytial cells with indistinct cell membranes and eosinophilic cytoplasm; High power view exhibiting cohesive nests and whorls of plump polygonal meningothelial cells with oval nuclei, finely dispersed chromatin, indistinct cell borders, interspersed with spindle cells exhibiting elongated nuclei and eosinophilic cytoplasm.

Discussion

Meningiomas are the most common intracranial tumors arising from the meninges. Pineal tumors, on the other hand, are rare, comprising only 0.5–1.6% of all intracranial tumors, and meningiomas represent a rare subgroup among these.[6, 7] Tumors occurring in the pineal region may be neoplastic or non-neoplastic. Non-neoplastic lesions include pineal cysts, cystic lesions (arachnoid cysts or epidermoid cysts), and vascular abnormalities. Neoplastic lesions include pineal parenchymal tumors (pineocytomas and pineoblastomas), germ cell tumors (germinomas, non-germinomatous germ cell tumors, and teratomas). These lesions present with varied clinical symptoms such as headache, dizziness, visual disturbances, endocrine

dysfunction, and neurological deficits like impaired balance and cognitive decline.[6]

Pineal meningiomas are characterized by little or no dural attachment in contrast to meningiomas arising elsewhere. These tumors grow slowly into the pineal region and compress surrounding structures such as the pineal gland, midbrain, deep venous system, and the third ventricle. Radiologically, they are subdivided into two types: those at the falcotentorial junction (origin unclear) and those at the velum interpositum (thought to arise from arachnoid cap cells).[7,8] Falcotentorial meningiomas arise from the junction of the dural folds between the falx cerebri and tentorium cerebelli. Velum interpositum meningiomas arise from the double-layered pia of the velum interpositum and have no direct dural attachment.[7,8]

WHO grading of meningiomas depends on histologic subtype and is divided into Grade 1 to 3. Grade 1 meningiomas are the most common subtypes encountered in practice and also the most commonly reported in the pineal region.[9] Fukushima *et al.* described a rare case of chordoid pineal meningioma (WHO Grade 2) in a 22-year-old female.[10] Our case was of a transitional meningioma, a Grade 1 tumor composed of mixed meningothelial and fibroblastic areas, generally associated with a good prognosis. Treatment of pineal region involves surgical resection with minimal damage to surrounding brain structures.[6]

Inoue *et al.* described two cases of transitional pineal meningiomas derived from the arachnoid membrane over the vein of Galen without dural attachment.[7] Our case was a falcotentorial meningioma classified as a transitional meningioma on histopathology. Yu *et al.* studied 21 cases of pineal meningioma and categorized them as arising from either the falcotentorial junction or the velum interpositum. Falcotentorial meningiomas were further divided as arising from the falx cerebri, tentorium cerebelli, and straight sinus, while velum interpositum meningiomas arose from the arachnoid sleeve of the Galen vein, internal cerebral vein, and the posterior surface of the pineal gland. Out of the 21 cases, 16 underwent total resection, while 5 had subtotal resections.[9]

The pineal gland lies in a critical anatomical location, closely related to the midbrain. Tumors here typically cause dorsal midbrain compression leading to signs of obstructive hydrocephalus and focal neurological deficits.[5] Hydrocephalus is the most common clinical presentation. Our patient showed symptoms of raised intracranial pressure (headache and vomiting), along with Parinaud's syndrome and papilledema.

Germ cell tumors are the most common tumors of the pineal region, with germinomas accounting for 50%, teratomas 15%, and choriocarcinomas 5%. However, serum markers for these tumors were non-contributory in our case. A diagnosis of pineal region tumor is made based on a combination of clinical history, neurological examination, neuroimaging, and tumor markers.[5]

Although radiological overlap exists among pineal lesions, in most cases a distinction between benign and malignant tumors can be made. Radiology also helps assess whether the tumor is unifocal or multifocal.[6.] In our case, MRI was suggestive of meningioma, clearly delineating its location, origin, and relation to surrounding structures. This information was crucial for planning the surgical approach and determining whether complete resection was feasible. Falcotentorial meningiomas can closely mimic primary pineal region tumors on imaging due to their deep location and mass effect on adjacent structures. Differentiating these entities preoperatively is crucial, as it directly influences surgical approach and risk of injury to the deep venous system. Recognition of imaging features such as dural attachment, venous displacement patterns, and absence of tumor marker elevation can aid in narrowing the diagnosis.[6-7]

In our case, surgical resection with complete excision was performed via the interhemispheric approach. Other possible surgical routes include the occipital transtentorial and infratentorial cerebellar approaches, depending on tumor anatomy and surgeon preference.[11,12]

Meningiomas can be categorized by size. Bellur SN, in an autopsy study of 76 meningiomas, defined tumors with diameters between 0.5–2.7 cm as small, and 2.8–10.5 cm as large. Lesions >5 cm in maximum diameter are classified as giant meningiomas.[3] However, giant meningiomas in the pineal region are exceedingly rare.[13] The size of the tumor in our patient (5.3 × 4.5 × 4.2 cm) qualifies it as a large falcotentorial meningioma. Prognosis and outcome in pineal meningioma depend on the degree of encroachment on surrounding structures and the

completeness of resection. Radiological imaging plays a vital role in preoperative planning, while histopathology is essential for diagnostic confirmation and tumor grading.[11]

Conclusion

Large falcotentorial meningiomas presenting as pineal region masses are uncommon and pose significant surgical challenges due to their deep location and intimate relationship with the quadrigeminal plate and deep venous complex. Careful preoperative imaging, appropriate selection of surgical approach, and meticulous microsurgical technique are critical to achieving gross resection while preserving neurological function. This case underscores the importance of considering meningioma in the differential diagnosis of pineal region lesions and highlights key operative considerations in their management.

Abbreviations

PTs – Pineal Region Tumors; MRI – Magnetic Resonance Imaging; T1 – T1-weighted imaging (a type of MRI sequence); T2/FLAIR – T2-weighted/Fluid-Attenuated Inversion Recovery (MRI sequence); DWI – Diffusion weighted imaging; CSF – Cerebrospinal Fluid; HCG – Human Chorionic Gonadotropin; CEA – Carcinoembryonic Antigen; AFP – Alpha-Fetoprotein; ALP – Alkaline Phosphatase; VP Shunt – Ventriculoperitoneal Shunt; WHO – World Health Organization; CNS – Central Nervous System.

Author contributions

Conceptualisation: SZ, SC. Writing – original draft: SC, SA, VG, AS. Writing – review and editing: SZ, SA, VG, AS. Supervision: SZ, SA.

References

1. Gagliardi F, De Domenico P, Garbin E, Snider S, Mortini P. Primary gamma knife radiosurgery for pineal region tumors: a systematic review and pooled analysis of available literature with histological stratification. J Pineal Res 2023;75(4).
2. Smith AB, Rushing EJ, Smirniotopoulos JG. From the archives of the AFIP: lesions of the pineal region: radiologic-pathologic correlation. Radiographics 2010;30:2001–2020.
3. Armocida D, Catapano A, Palmieri M, Arcidiacono UA, Pesce A, Cofano F, *et al.* The surgical risk factors of giant intracranial meningiomas: a multicentric retrospective analysis of large case series. Brain Sci 2022;12:817.
4. Alves Junior AC, Botta FP, Hamamoto Filho PT, Zanini MA. Occipital interhemispheric transtentorial approach for a pineal region meningioma with pseudobulbar palsy. World Neurosurg 2022;161:71.
5. Lensing FD, Abele TA, Sivakumar W, Taussky P, Shah LM, Salzman KL. Pineal region masses: imaging findings and surgical approaches. Curr Probl Diagn Radiol 2015;44:76–87.
6. Ravipati C, Vikram MA, Ramakrishnan KK, Malaichamy A. Radiological insights from two distinct cases of pineal region meningioma: a case report. Cureus 2024;16:e57796.
7. Inoue A, Ohnishi T, Kohno S, Ohtsuka Y, Nakamura Y, Mizuno Y, *et al.* Two cases of pineal-region meningiomas derived from arachnoid membrane over the vein of Galen without dural attachment. World J Surg Oncol 2015;13:226.
8. Ding Y, Sun L, Hu Y, Zhai W, Zhang L, Yu Z, *et al.* Combined microscopic and endoscopic surgery for pineal region meningiomas using the occipital-parietal transtentorial approach. Front Oncol 2022;12.
9. Yu L, Orazmyradov B, Qi S, Song Y, Fang L. Reinvestigation of the origins of pineal meningiomas based on its related veins and arachnoid membranes. BMC Neurol 2020;20:200.
10. Fukushima S, Terasaki M, Shigemori M. Chordoid meningioma arising in the pineal region: a case report. Brain Tumor Pathol 2008;25:91–95.
11. Gaillard F, Jones J. Masses of the pineal region: clinical presentation and radiographic features. Postgrad Med J 2010;86:597–607.
12. Tomita T. Pineal tumor. In: Selden N, Baird L, eds. Pediatric neurosurgery: neurosurgery by example. New York: Oxford Academic; 2019.
13. Bellur SN, Chandra V. Meningioma size: its relationship to other diseases. Arch Neurol 1981;38:458–459.